

Akami et al., Embolism development observed with a compact MRI in Japanese black pine clones resistant to pine wilt disease. In: Schröder, T. (ed.), Pine Wilt Disease Conference 2013, pp. 110-111, Braunschweig, ISSN: 1866-590X

(127) Embolism development observed with a compact MRI in Japanese black pine clones resistant to pine wilt disease

Akami A, Kusumoto D, Hirao T, Watanabe A, Fukuda K

The University of Tokyo, 5-1-5 Kashiwanoha, Kashiwa-shi, Chiba 277-8563, Japan

Email: aaai09a@nenv.k.u-tokyo.ac.jp

1. INTRODUCTION

The symptom development of pine wilt disease is divided into two stages, the early and advanced stages. In the early stage, pinewood nematodes (*Bursaphelenchus xylophilus*) mainly disperse in cortical and xylem resin canals, then induce parenchyma denaturation which cause xylem embolism partially. In the advanced stage, nematode population drastically increase, which coincides with cambial destruction and embolism development in the whole stem. Symptoms observed in resistant pines, which were selected in national projects, don't progress to the advanced stage in general. However, their resistance shows great variation among families or clones, which have been ranked from grade 1 (low) to 5 (high). In this study, to clarify the symptom development in detail, we examined embolism development in resistant pine clones inoculated with nematodes.

2. MATERIALS AND METHODS

Potted Japanese black pine (*Pinus thunbergii*) clones, two resistant (Tosashimizu 63 (grade 4), Oita 8 (grade 1)) and two susceptible (Kashima 2, Futaba 1) varieties, were used in this study. Virulent (S10) or avirulent (C14-5) isolates of pinewood nematodes reared on the fungus (*Botrytis cinerea*) were inoculated into 1-year-old stem of each seedling. Embolism development was observed in multi-cross-sectional slices taken with a compact MRI. At 16 positions along the stem at 1 cm intervals from 5 cm above to 10 cm below the inoculation point (0 cm), embolisms were monitored periodically.

3. RESULT

Xylem embolism only occurred around inoculation site in all clones inoculated with avirulent nematodes. On the other hand, in the seedlings inoculated with the virulent nematodes, embolism occurred beyond the inoculation site even in the resistant clones,

but it enlarged more moderately in the resistant clones than in the susceptible ones. The pattern of the embolism development in the highly resistant clone (Tosashimizu 63) spread from outer to inner xylem along ray tissues regardless of distance from the inoculation site, while in the lower resistant (Oita 8) and the susceptible (Kashima 2, Futaba 1) clones, xylem embolism was mainly enlarged as a cluster from the inoculation site vertically and horizontally (Figure 1).

4. DISCUSSION

Avirulent nematodes did not induce embolisms in xylem except the inoculation sites even in susceptible clones, while virulent isolate induced embolism in resistant clones. This indicates that some numbers of virulent nematodes can migrate in xylem resin canals even in highly resistant clones. However, in the highly resistant clone, nematodes did not cause a mass embolism around the inoculation site. This may suggest that proliferation of nematodes around the inoculation site was inhibited in these seedlings.

In conclusion, restricted development of mass embolisms corresponded to the suppression of symptoms development to the advanced stage in resistant pine clones.

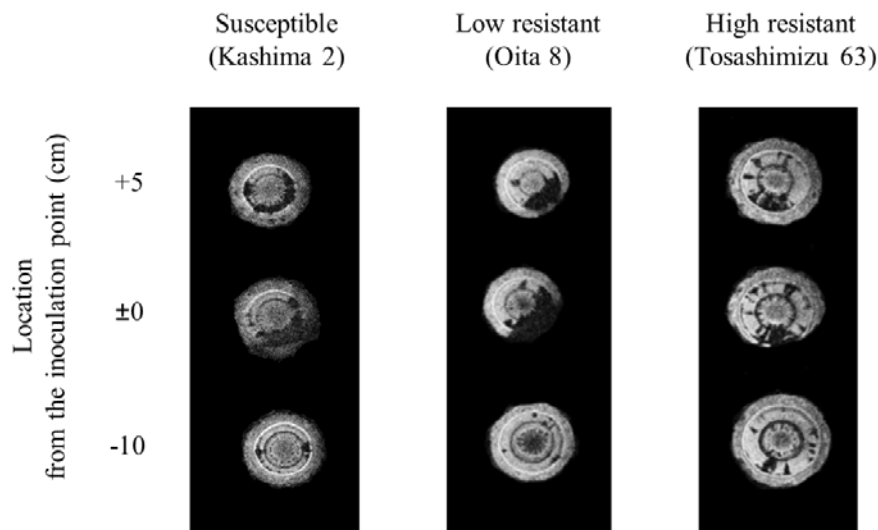


Figure 1. Embolism pattern in pine clones observed with a compact MRI